



**PROSTHODONTIC MANAGEMENT OF
SEGMENTAL MANDIBULECTOMY
WITH
IMPLANT SUPPORTED FIXED PROSTHESIS AND GUIDE PLATE**

DR. JAIMIN PATEL



**PRE-OP
CONDITION**

PRE-OP CONDITION



Difficulties in this case:

Restricted Mouth Opening

Very Stiff Right Buccal Mucosa

Left Skin Graft in Cheek – Non Flexible

Deviated lower jaw on left side

No guidance for occlusion

11

21

H

31

4B

Dr Jaimin Patel

R

I

F

11

21

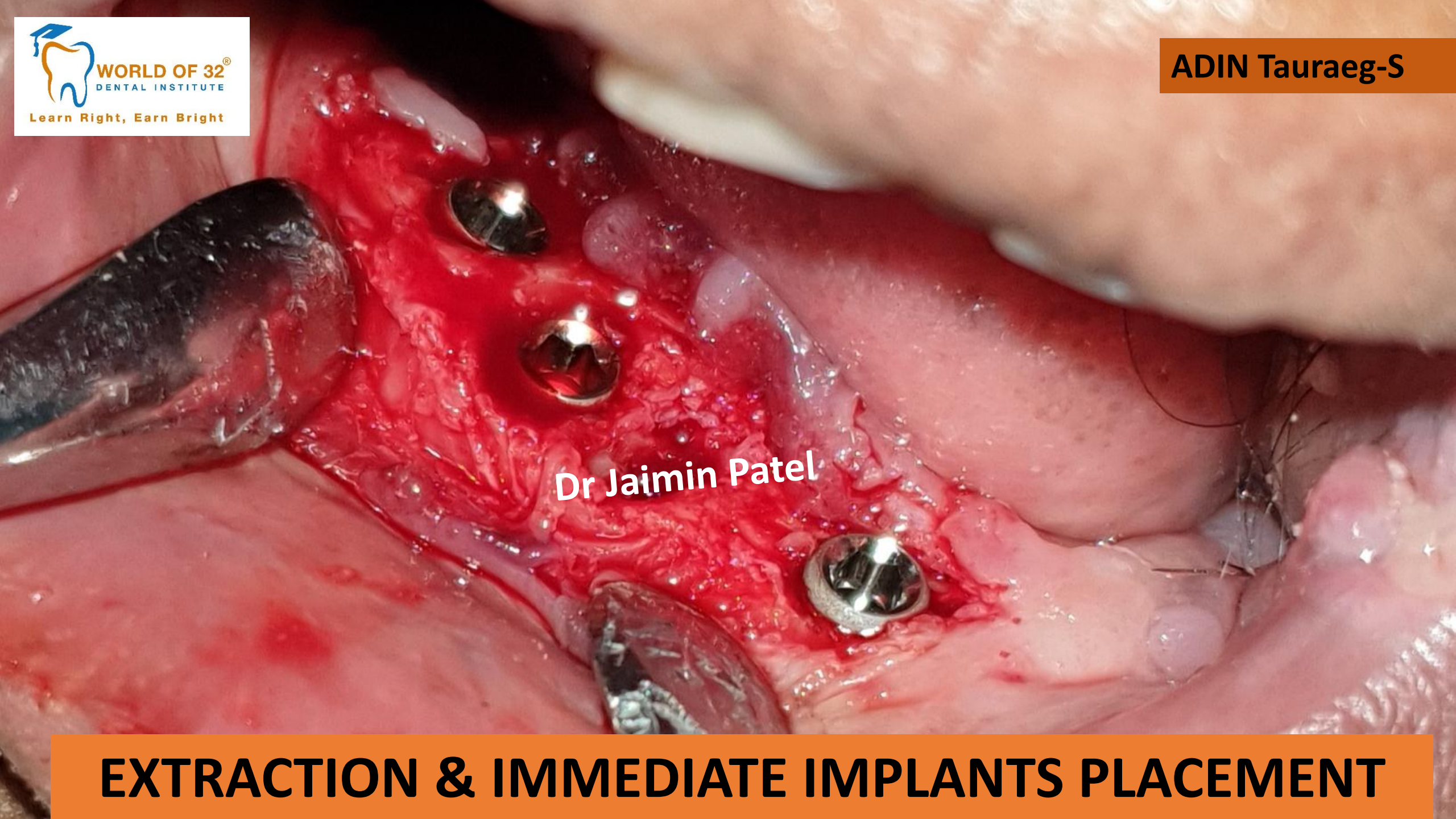
31

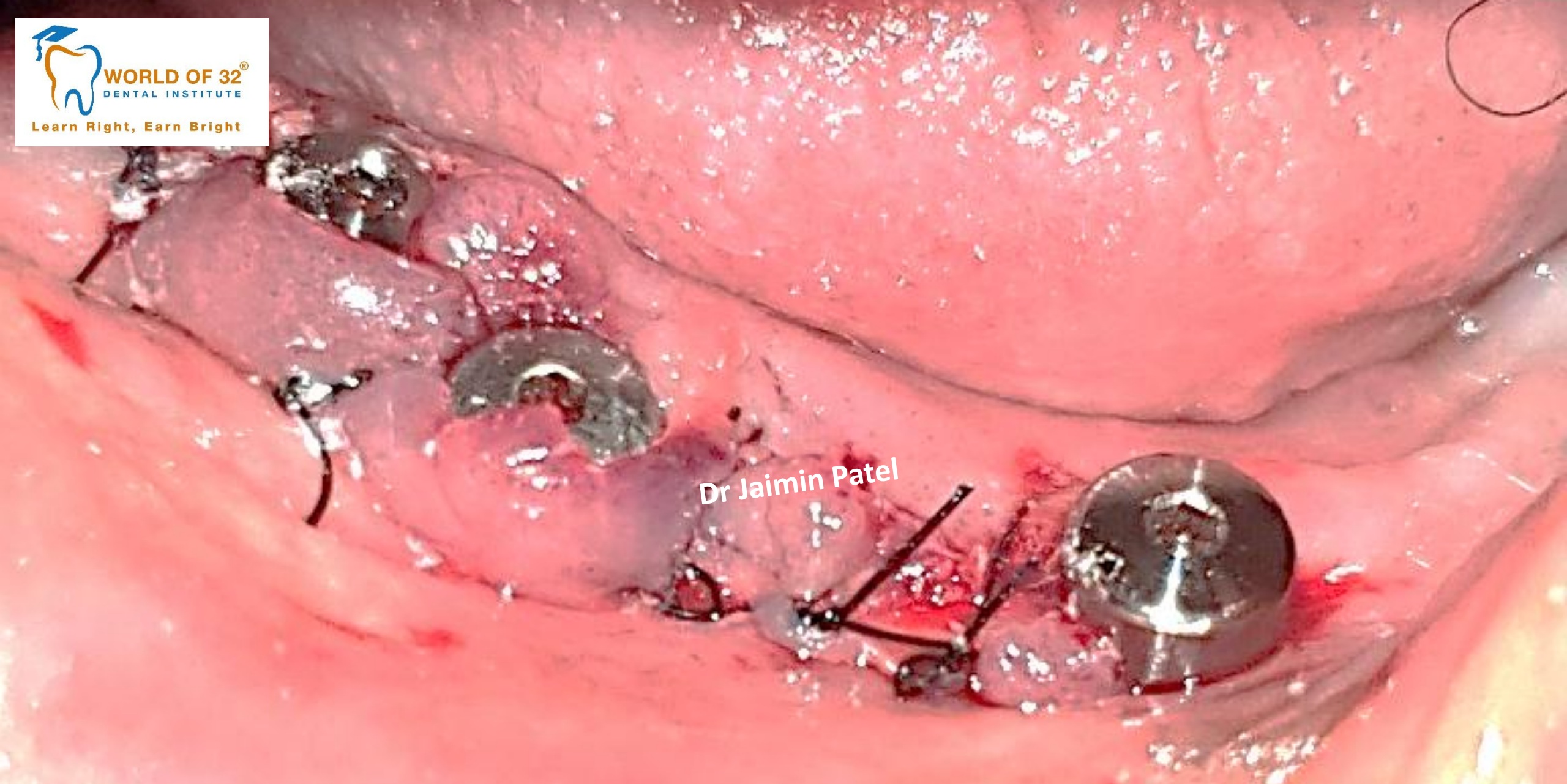
4B

PRE-OP CBCT

Dr Jaimin Patel

EXTRACTION & IMMEDIATE IMPLANTS PLACEMENT



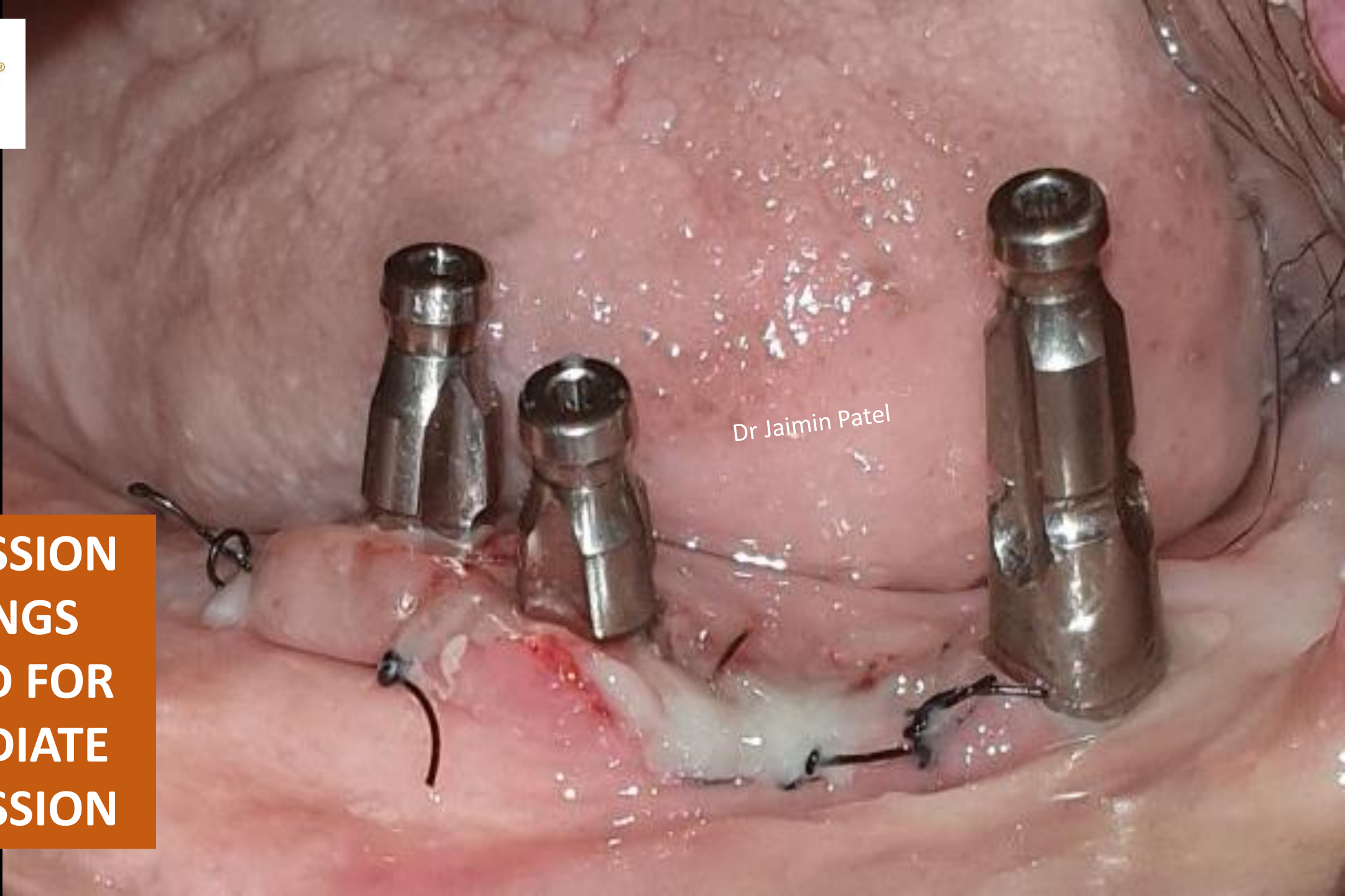

Dr Jaimin Patel

HEALING ABUTMENTS PLACED OVER IMPLANTS ON THE SAME DAY

**IMPRESSION
COPINGS
PLACED FOR
IMMEDIATE
IMPRESSION**

Dr Jaimin Patel

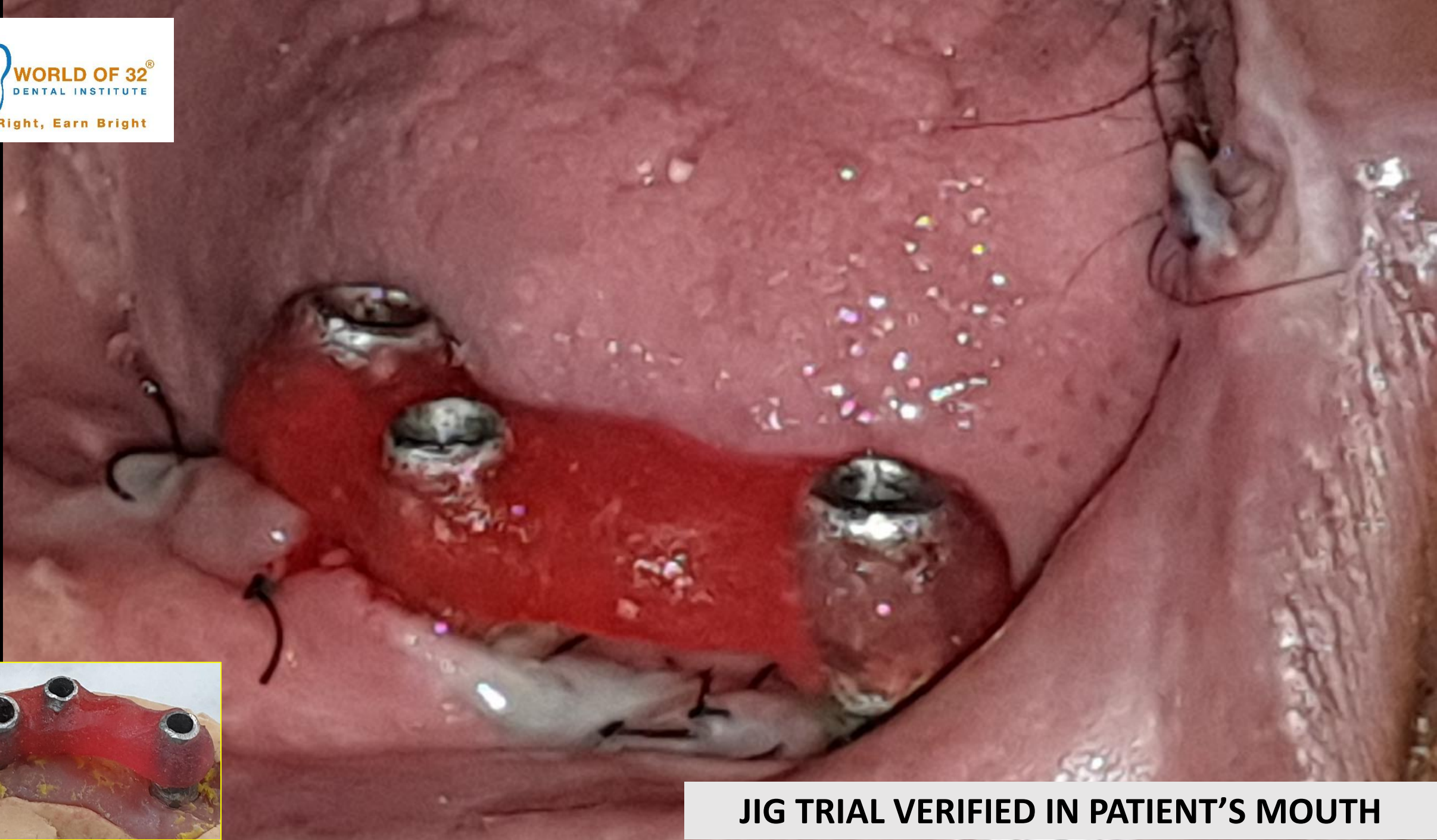




Dr. Jaimin Patel

Dr. Jigar Sodha

**MANDIBULAR
CLOSED TRAY
IMPRESSION**



JIG TRIAL VERIFIED IN PATIENT'S MOUTH

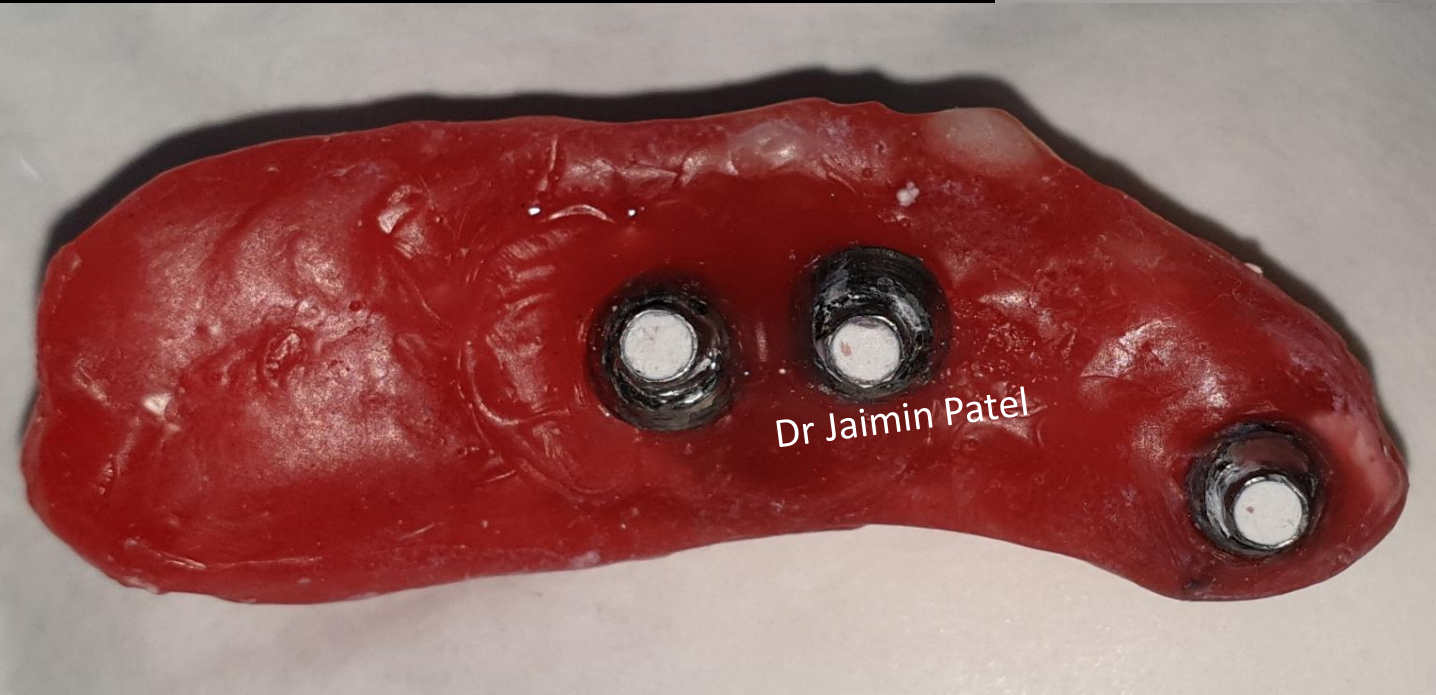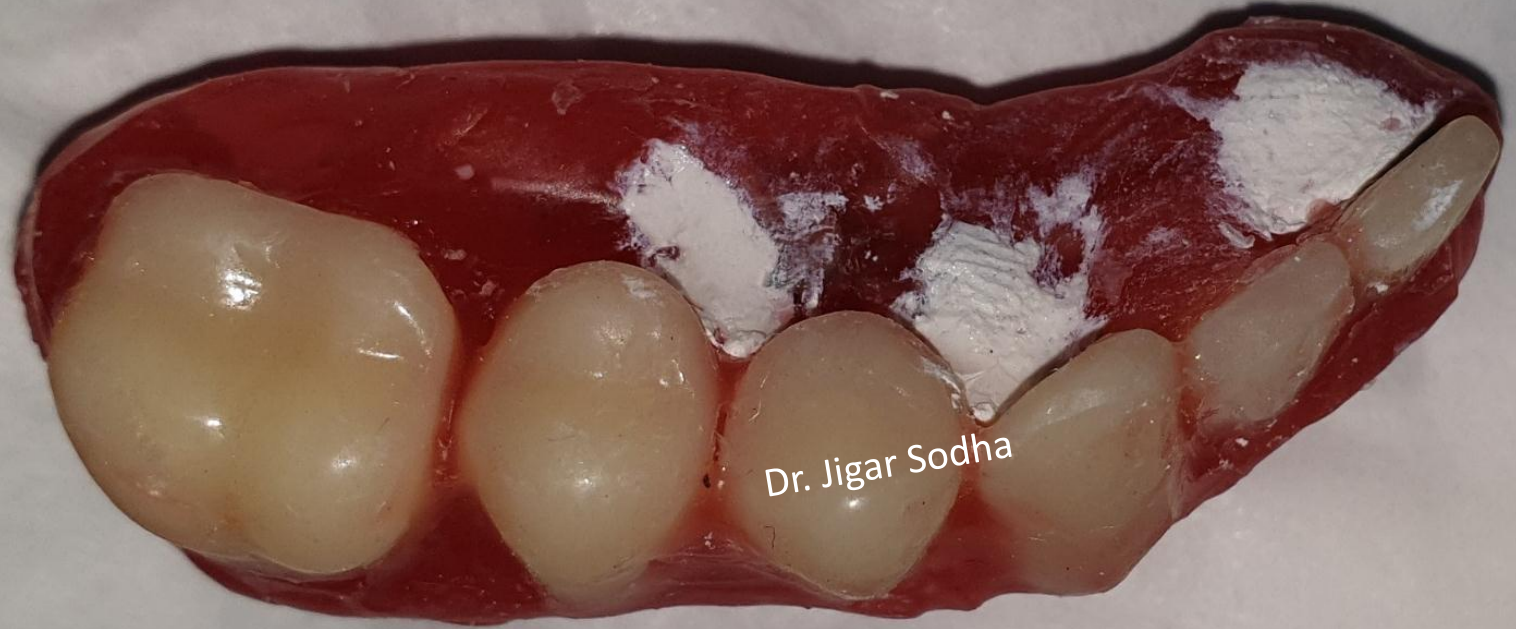EXTRA-ORAL WELDING

Dr Jaimin Patel

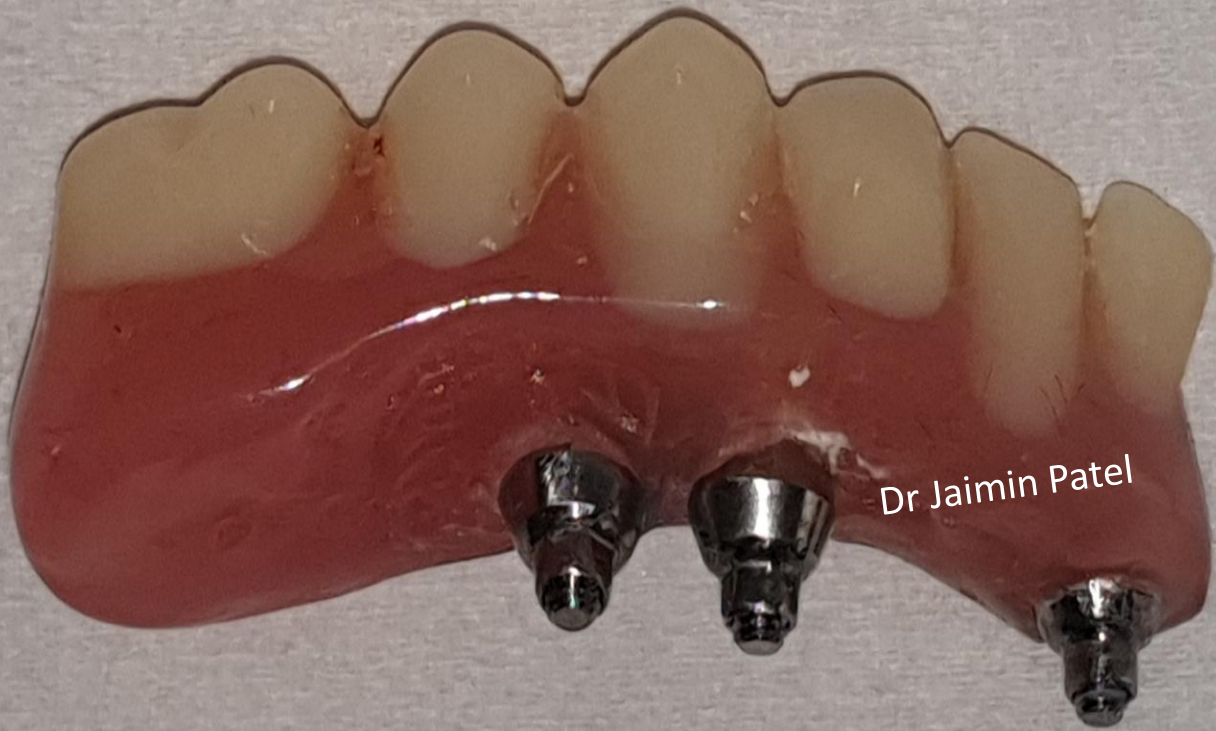


Dr Jaimin Patel

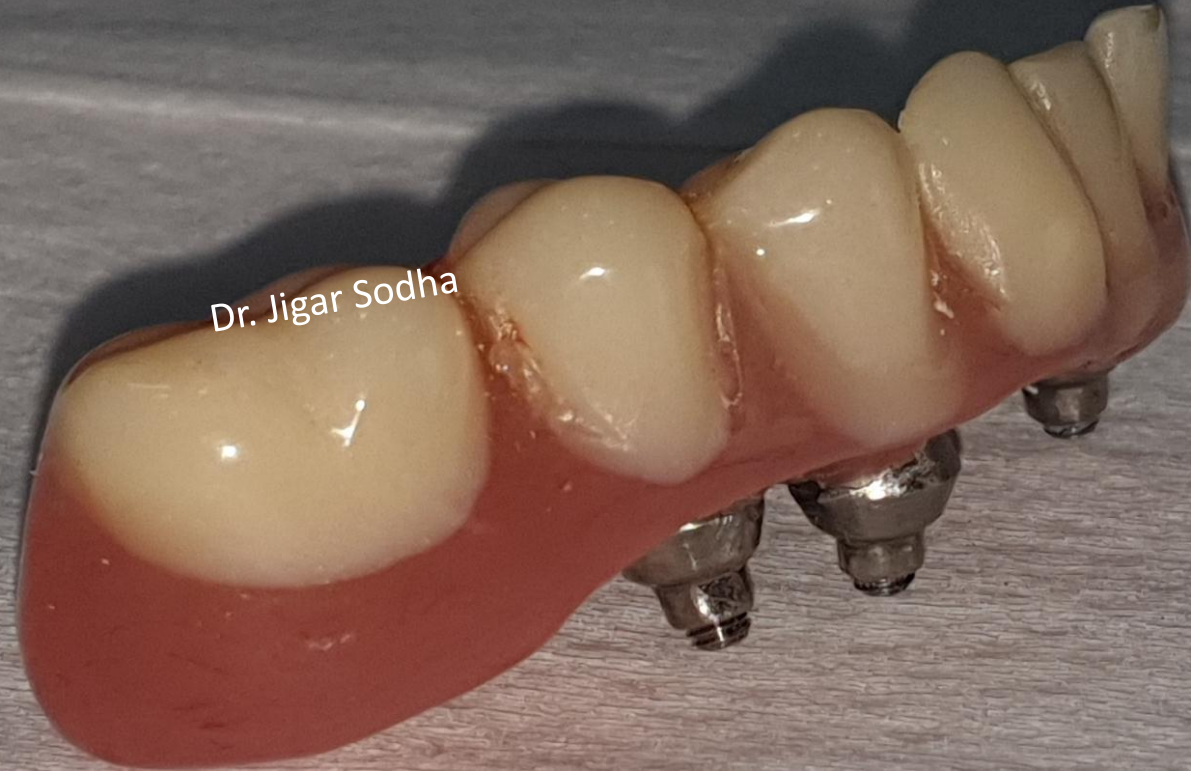

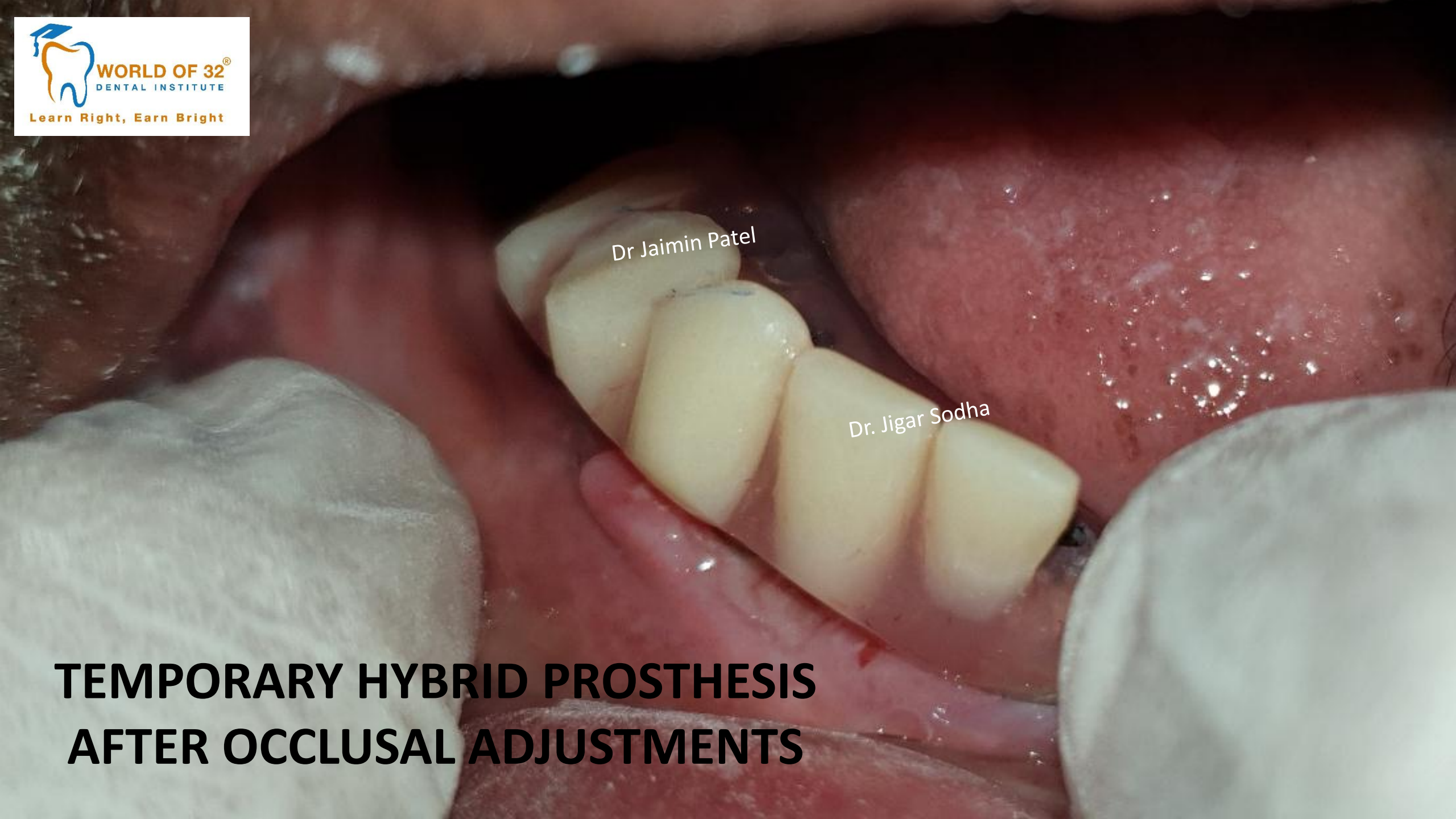


TEETH SETTING TRIAL



**TEMPORARY
HYBRID
PROSTHESIS**



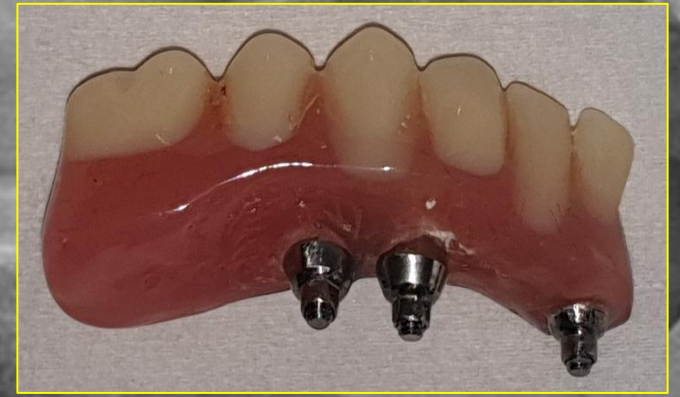

Dr Jaimin Patel

Dr. Jigar Sodha

**TEMPORARY HYBRID PROSTHESIS
AFTER OCCLUSAL ADJUSTMENTS**

IMMEDIATE PROVISIONAL HYBRID PROSTHESIS IN PLACE



Dr. Jigar Sodha

Dr Jaimin Patel

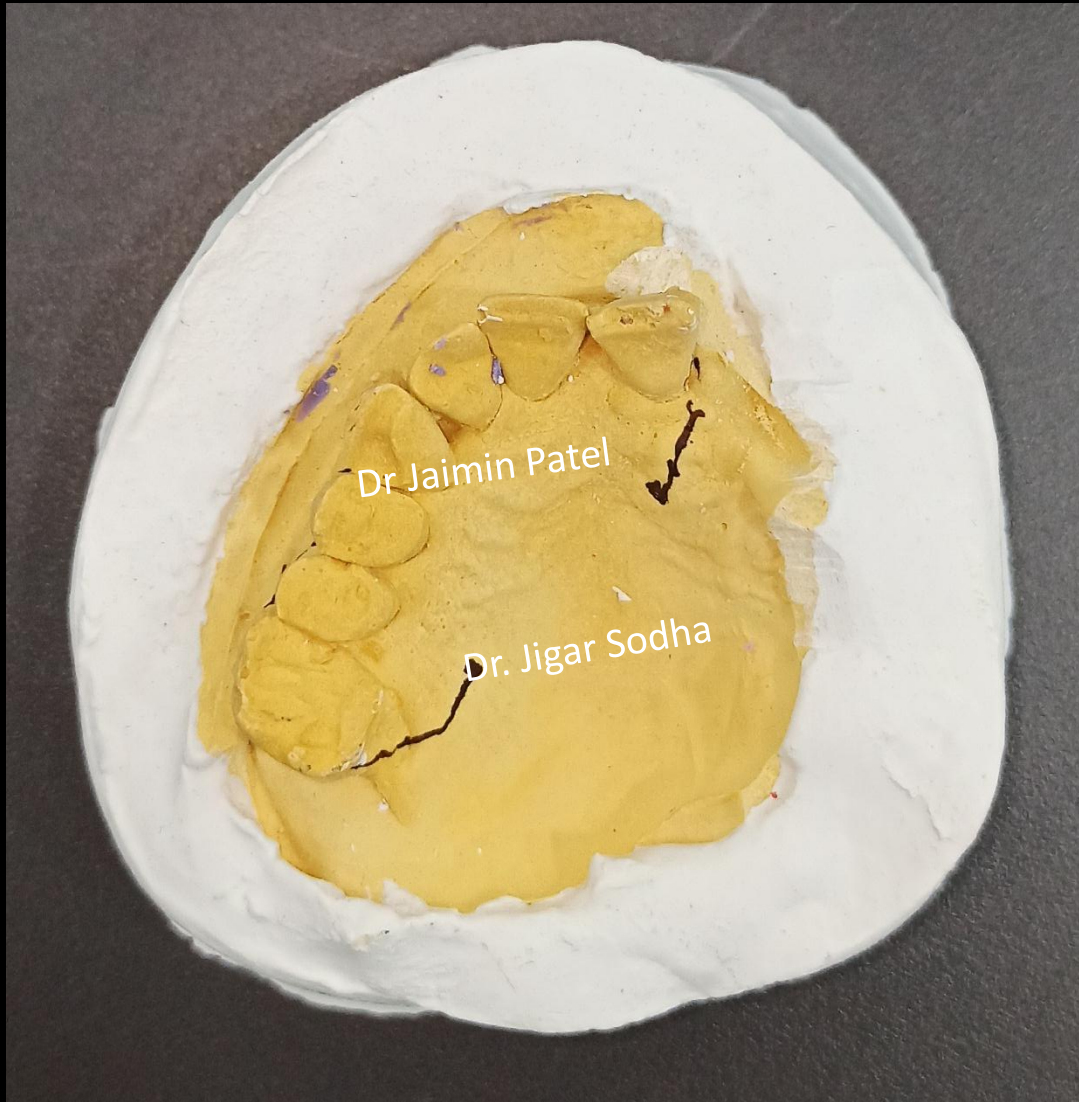
FINAL PROSTHESIS PROCEDURE

after 3 months

MAXILLARY IMPRESSION

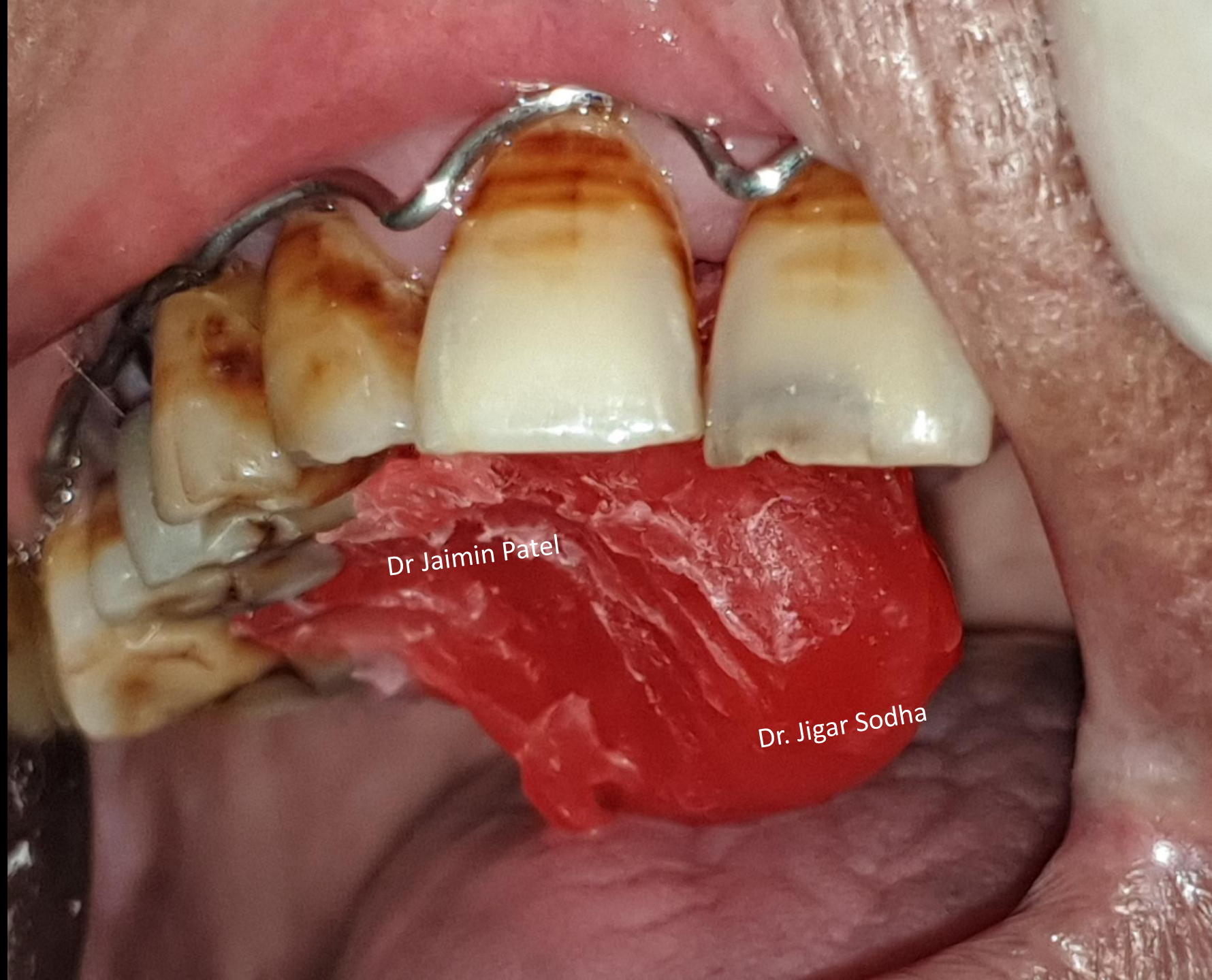
Dr Jaimin Patel

Dr. Jigar Sodha



MAXILLARY CAST AND TRIAL DENTURE BASE

TRIAL DENTURE BASE WITH OCCLUSAL RIM

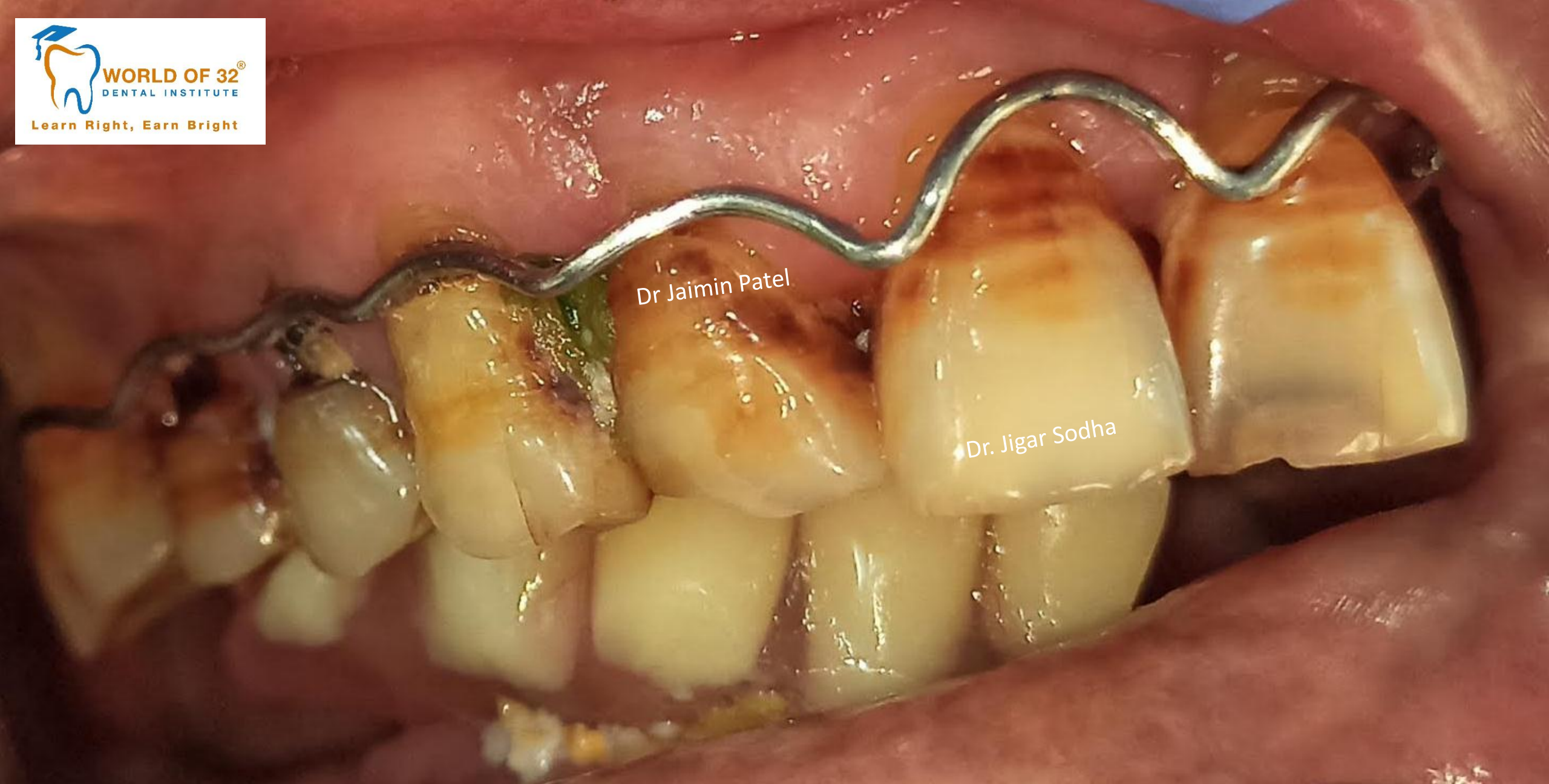


Dr Jaimin Patel

Dr. Jigar Sodha

GUIDE FLANGE PROSTHESIS

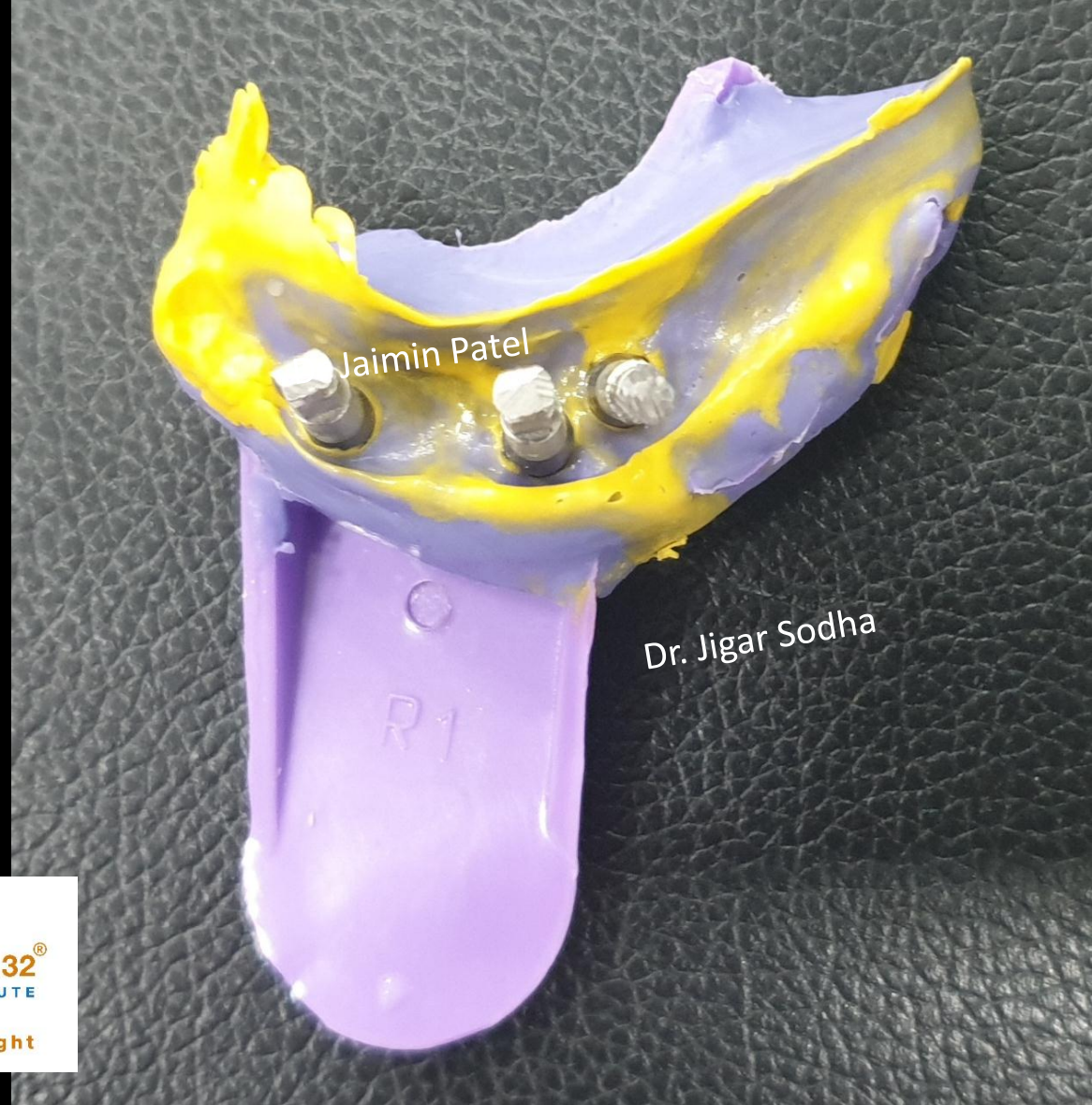
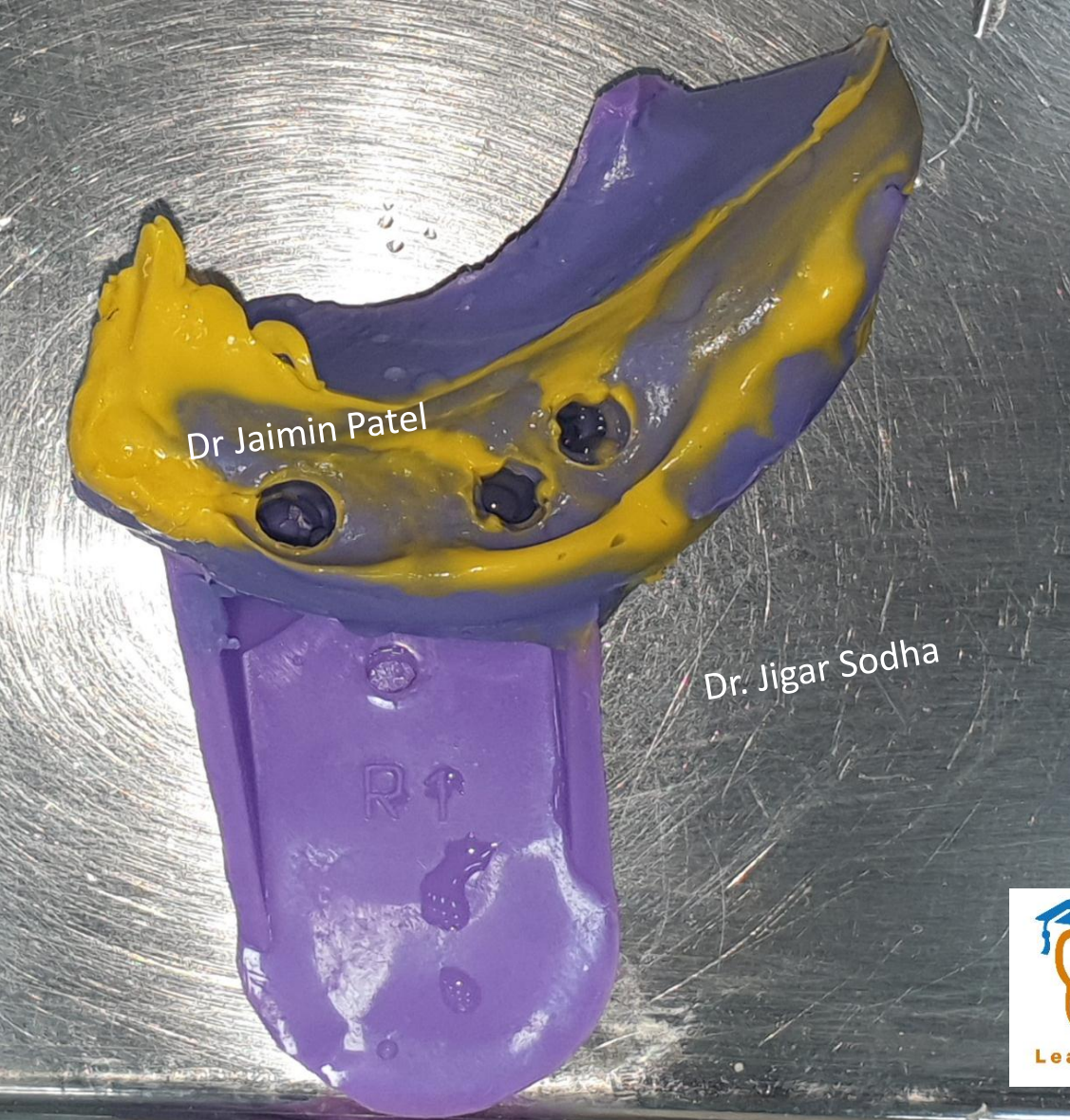




Dr Jaimin Patel

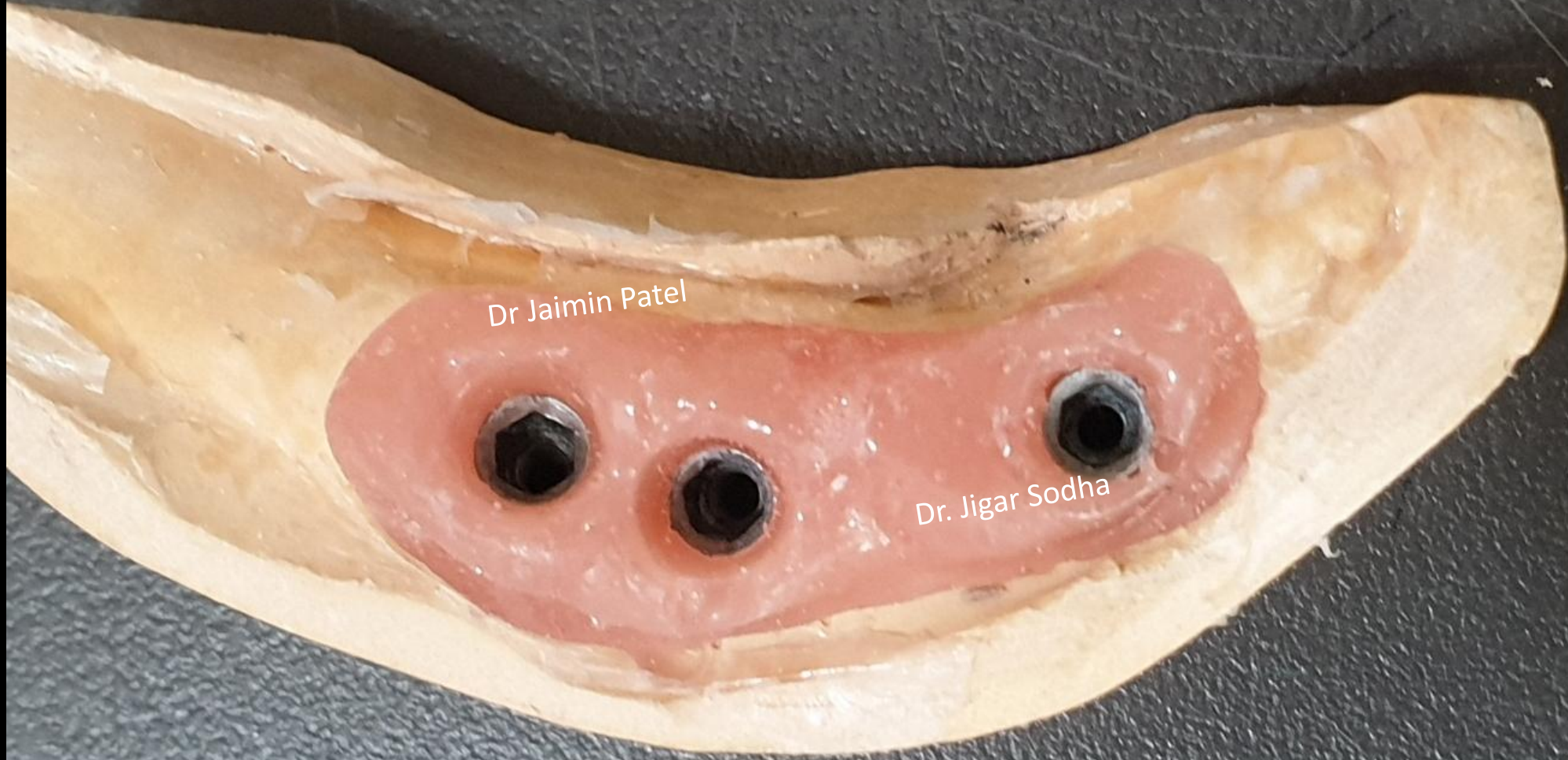
Dr. Jigar Sodha

TEMPORARY PROSTHESIS USED AS GUIDE FOR JAW RELATION



MANDIBULAR FINAL CLOSED TRAY IMPRESSION WITH ANALOGUES ATTACHED

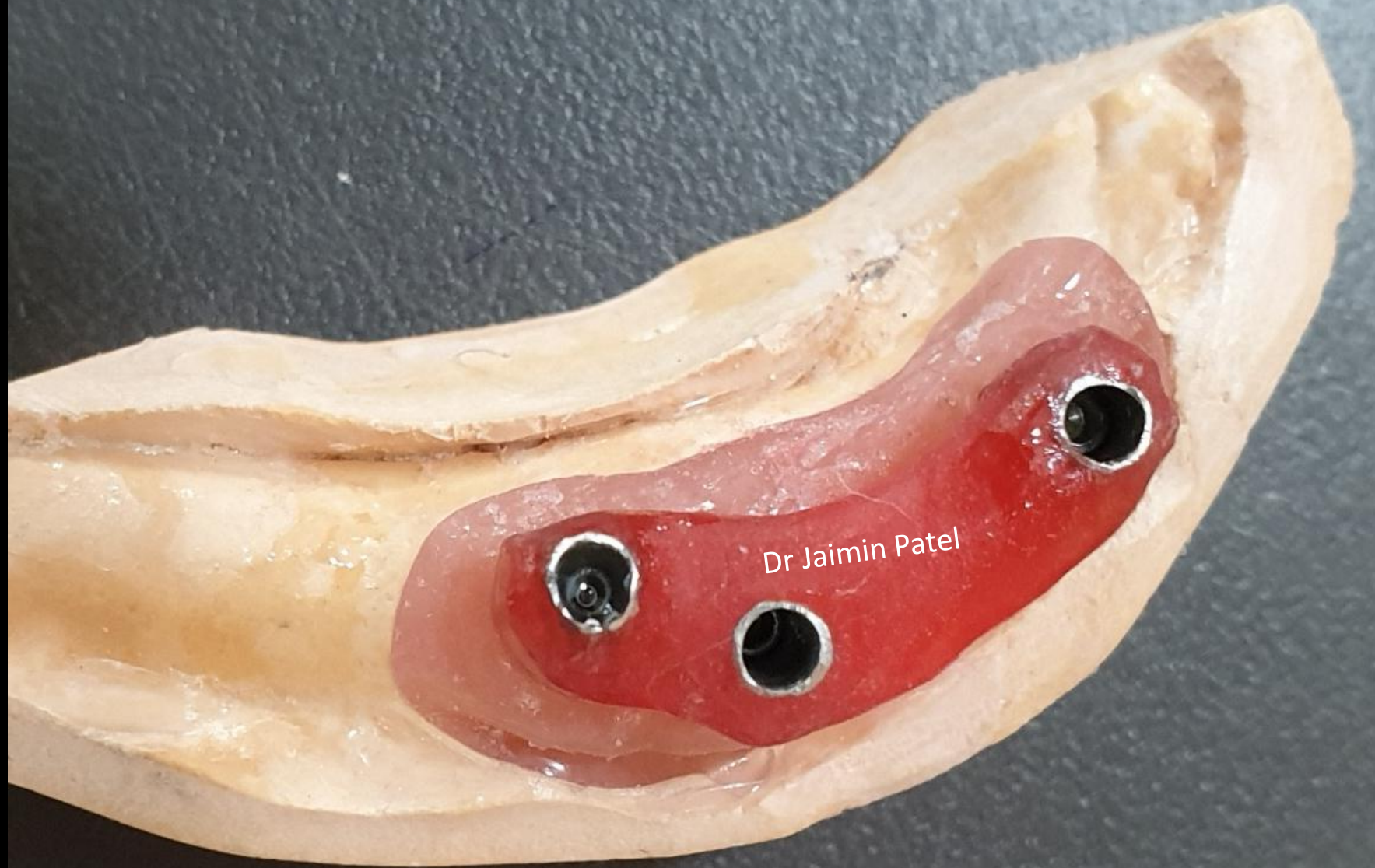MASTER CAST



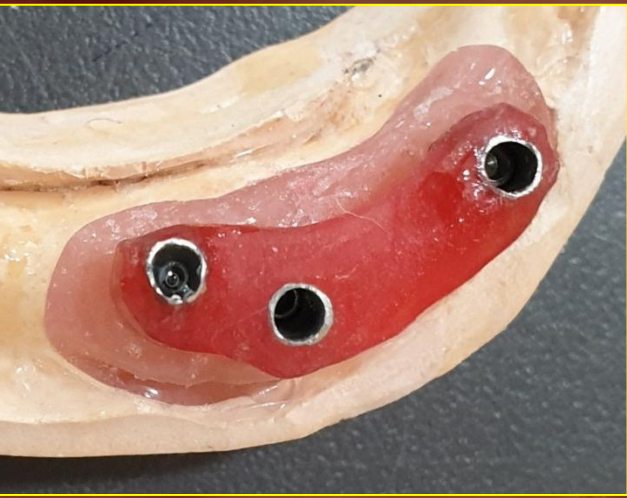
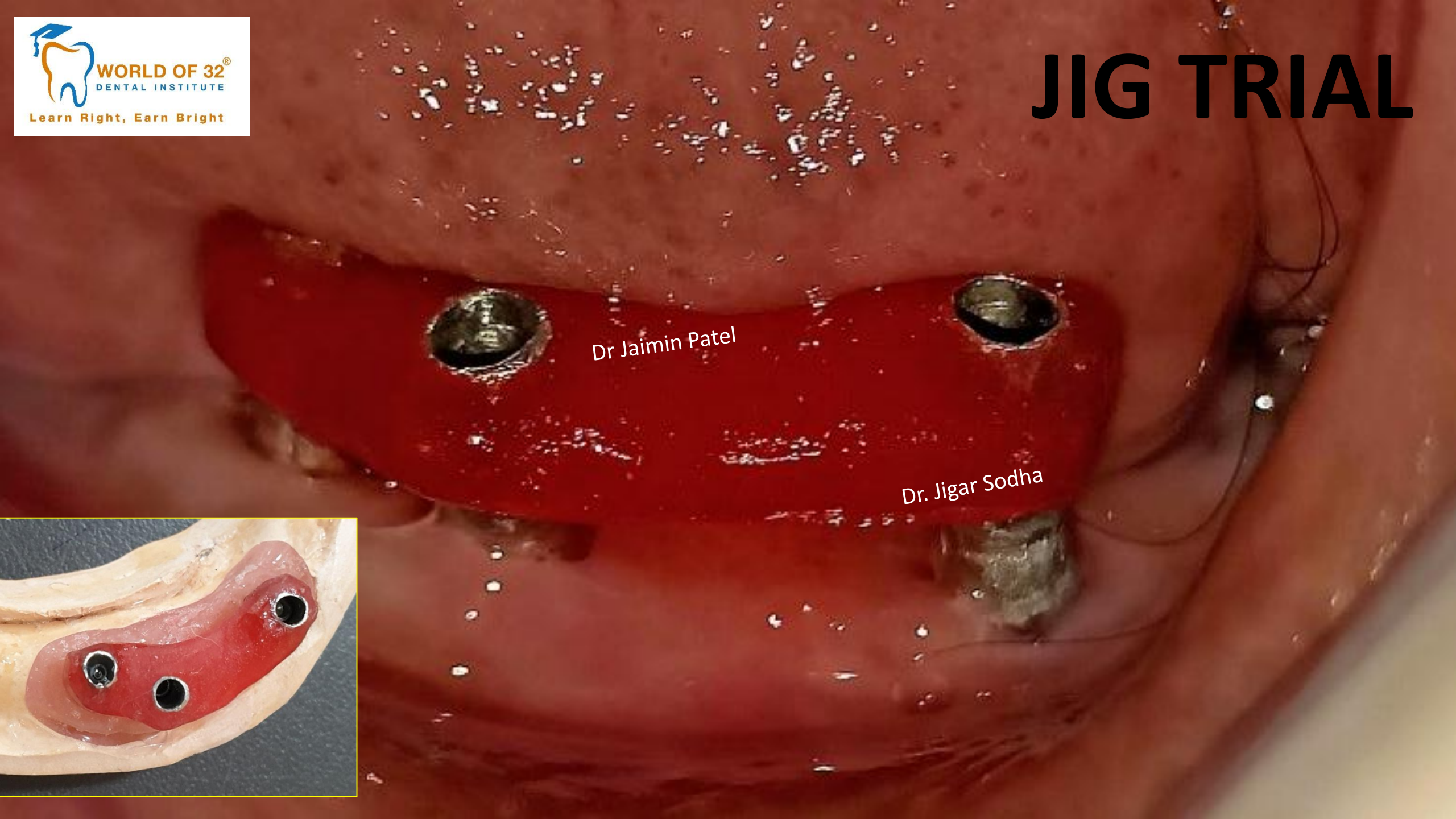Dr Jaimin Patel

Dr. Jigar Sodha

JIG TRIAL



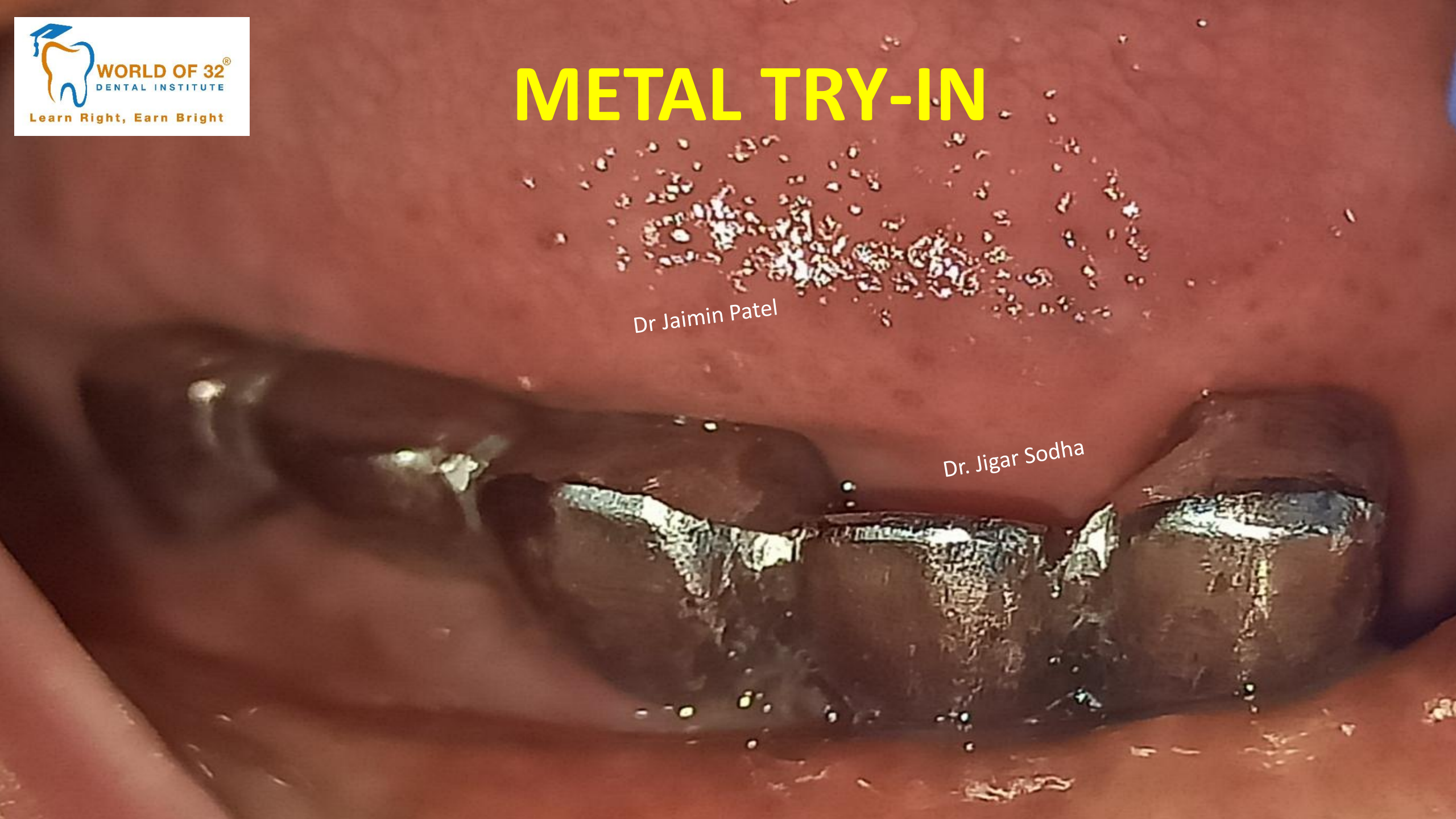JIG TRIAL



METAL TRY-IN

Dr Jaimin Patel

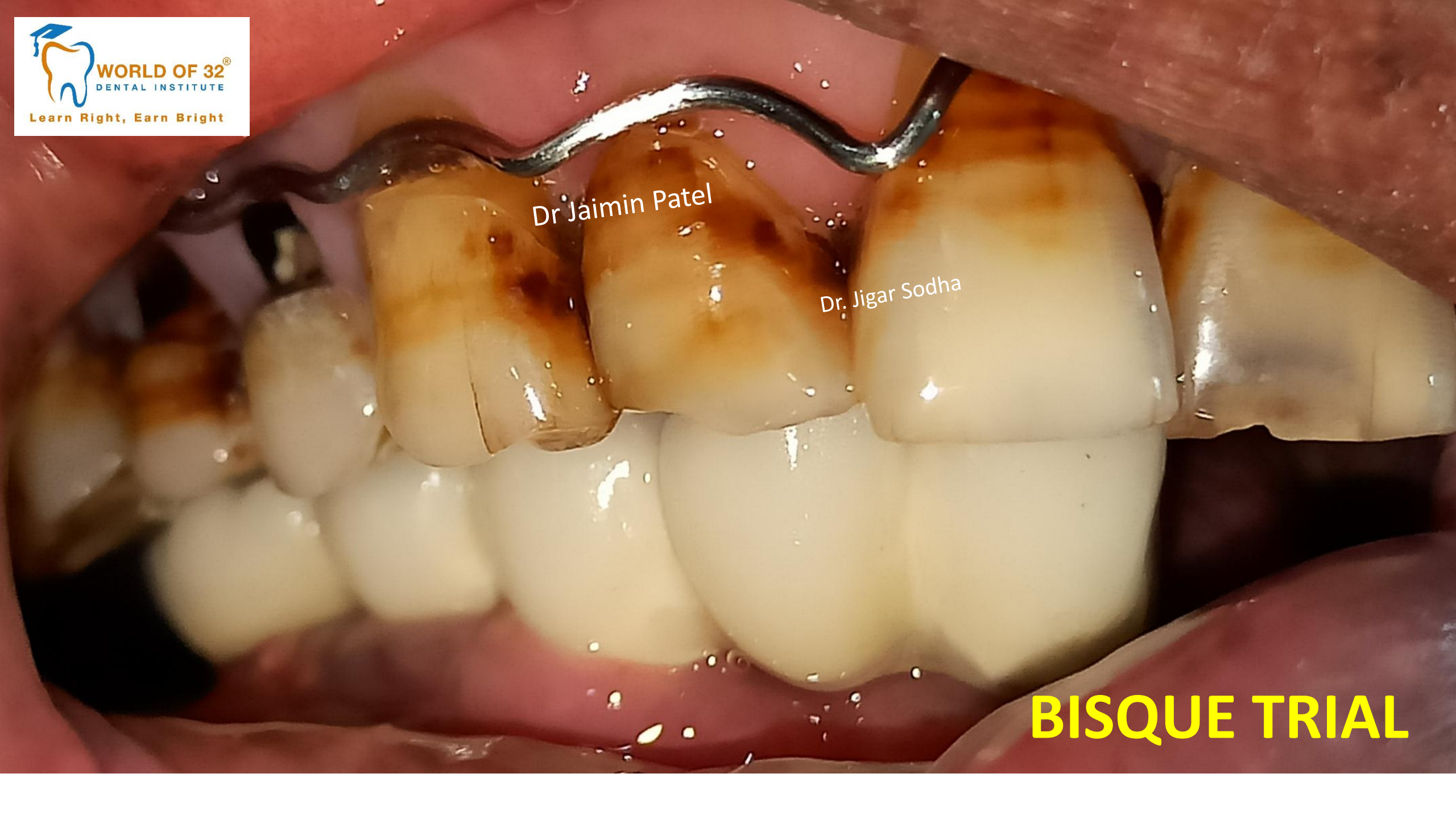Dr. Jigar Sodha



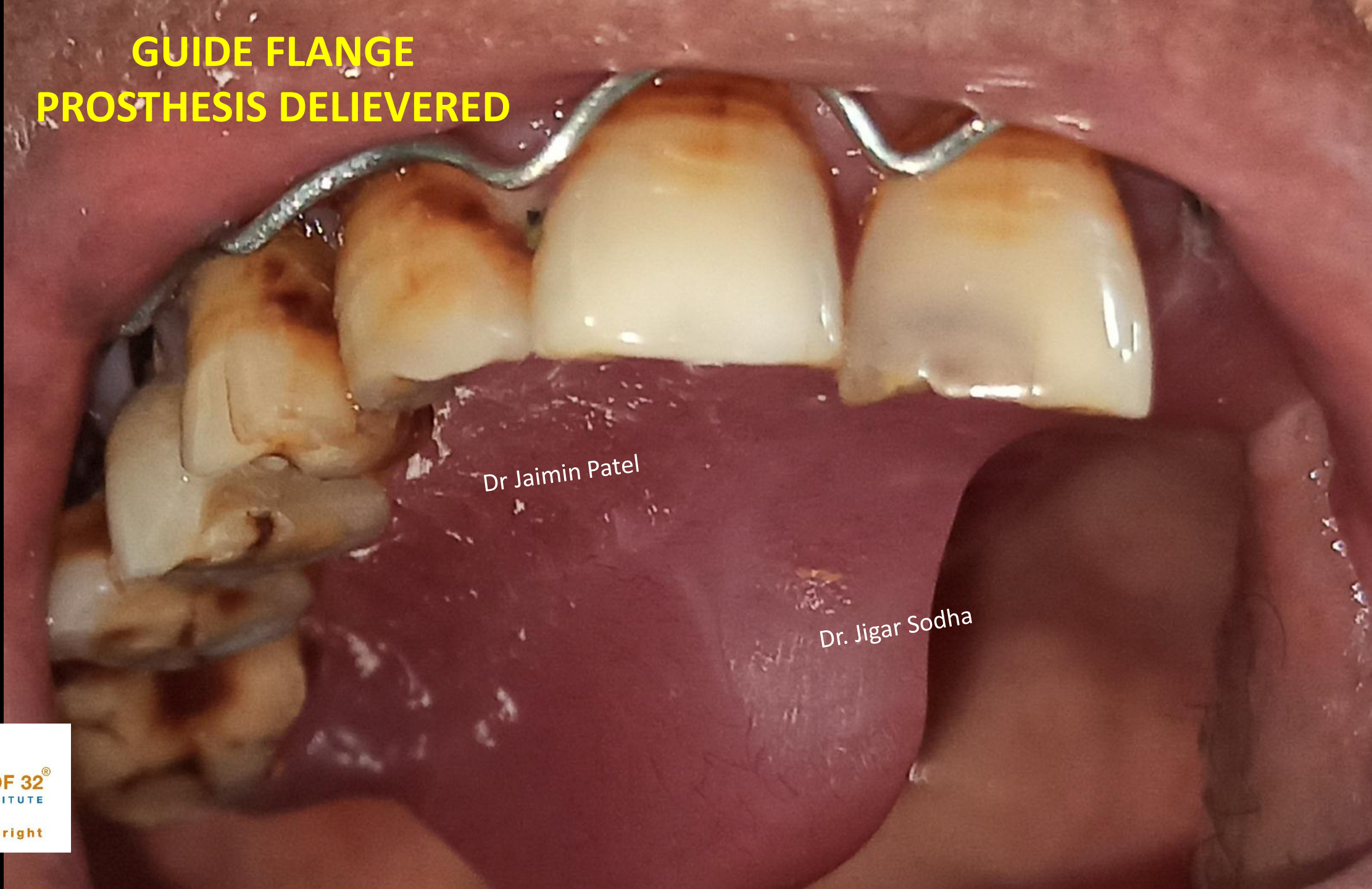
Dr Jaimin Patel

Dr. Jigar Sodha

BISQUE TRIAL



**GUIDE FLANGE
PROSTHESIS DELIVERED**



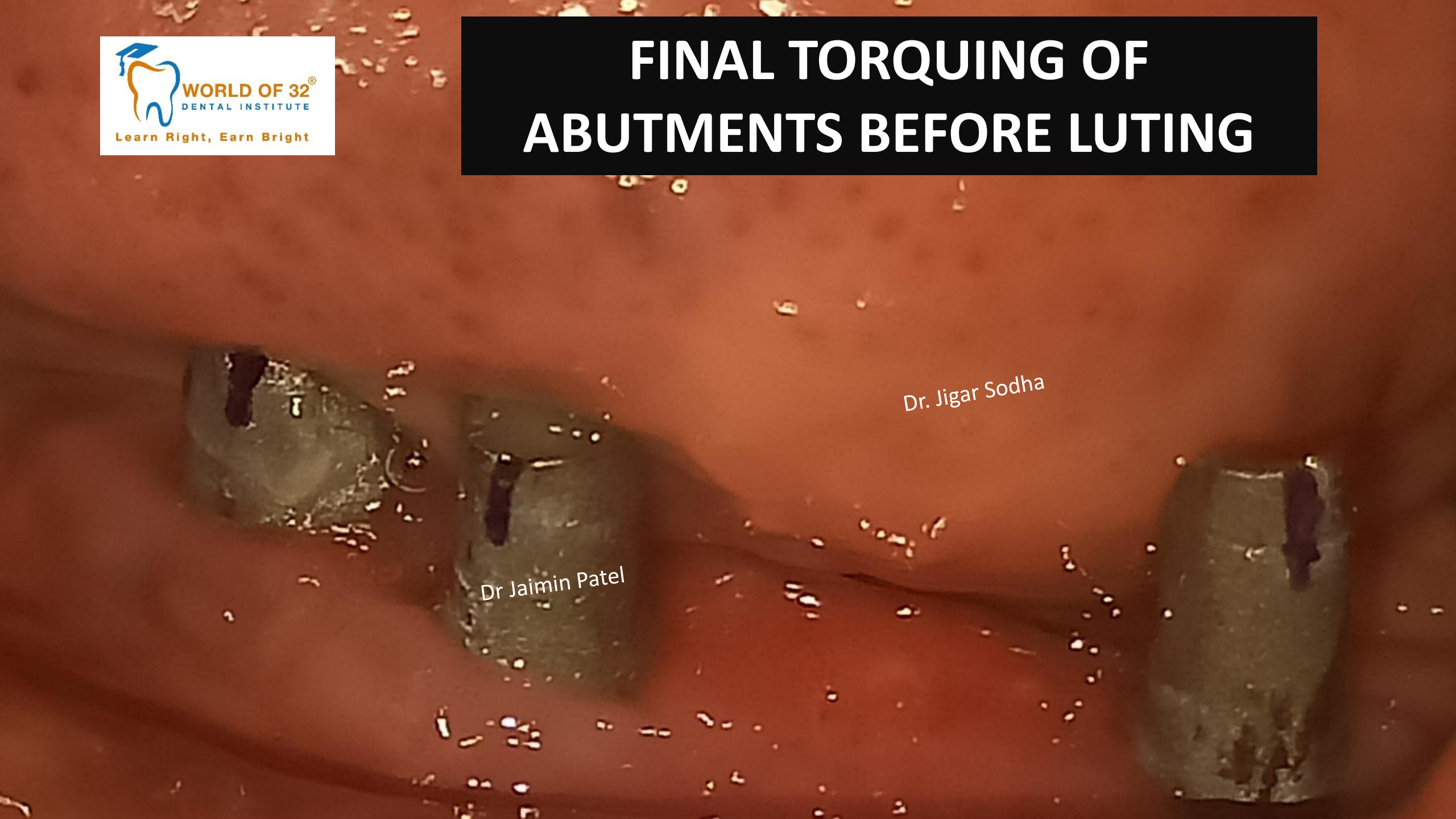
Dr Jaimin Patel

Dr. Jigar Sodha

FINAL TORQUING OF ABUTMENTS BEFORE LUTING

Dr. Jigar Sodha

Dr Jaimin Patel



Abutments Torqued

Dr Jaimin Patel

ADIN Tauraeg-S implants

FINAL OUTCOME

Dr Jaimin Patel

Dr. Jigar Sodha

Maximum Inter Cuspation

Dr Jaimin Patel

Dr. Jigar Sodha

FINAL OUTCOME

Dr. Jigar Sodha

Dr Jaimin Patel